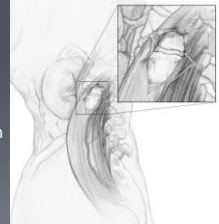


## EMG Evidence of Indirect Decompression during Lateral Transposas Interbody Fusion

M Woodall MD, B Shakir MD, A Smitherman MS, H Choudhri MD  
Georgia Health Sciences University

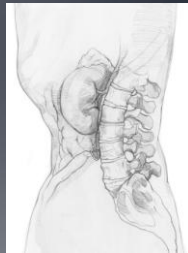
## Lateral Transposas Approach

- LTIF, LLIF, XLIF, DLIF
- Minimally invasive, Retroperitoneal Approach to the Lumbar Spine
- Achieves anterior interbody fusion
- May afford indirect decompression of the spinal canal and neural foramen
- Increasingly safe procedure



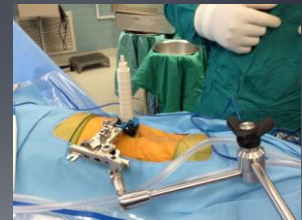## Anatomical Considerations

- Cleft between TP and posterior border of psoas
- Roots move dorsal to ventral at more caudal levels
- L3/4, L4/5 at relatively higher risk from a posteriorly situated retractor



## Neuromonitoring

- SSEP
- S-EMG
- T-EMG
- Directional Stimulation

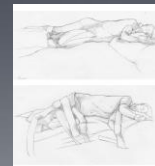

## Radiographic and Clinical Evidence of Indirect Decompression

- Oliviera et al.: 24.7% foraminal diameter  
33.1% canal diameter
- Elowitz et al.: increased canal area
- Kepler et al.: 35% foraminal area
- Clinical and radiographic data support indirect foraminal decompression after LTIF

## S-EMG and Nerve Root Compression

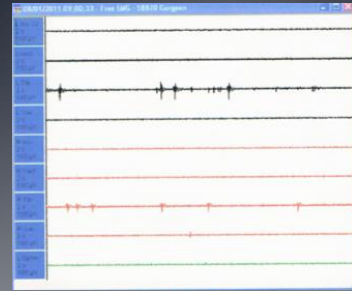
- S-EMG Discharge in 18% of cases
- Typically resolves with decompression
- May serve as an indicator of decompression



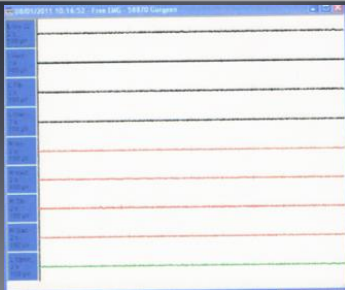
## EMG Evidence of Indirect Decompression

- S-EMG discharge at case outset
- S-EMG Quiet when trial inserted in the disk space
- S-EMG discharge returns when trial removed
- S-EMG quiet once interbody graft placed

## EMG Prior to Interbody Graft



## EMG After Interbody Graft



## Summary

- LTIF is an increasingly popular technique for anterior interbody fusion
- Clinical, Radiographic, and now EMG data support the notion of indirect decompression in LTIF
- Further study is needed to elucidate the clinical implications of these findings

## References

1. Bergey DL, Villavicencio AT, Goldstein T, et al. Endoscopic lateral transposas approach to the lumbar spine. *Spine* 2004;29:1681-8.
2. Rogers WB, Gerber EJ, Patterson JR. Intraoperative and early postoperative complications in extreme lateral interbody fusion (XLIF): An analysis of 600 cases. *Spine* 2011. Jan 1;36(1):26-32.
3. Evaluation of indirect decompression of the lumbar spinal canal following minimally invasive lateral transposas interbody fusion: radiographic and outcome analysis. Elowitz EH, Yanni DS, Chwajol M, Starke RM, Perin NI. *Minim Invasive Neurosurg*. 2011 Oct;54(5-6):201-6. Epub 2012 Jan 25. PMID: 22278702
4. Indirect foraminal decompression after lateral transposas interbody fusion. Kepler CK, Sharma AK, Huang RC, Meredith DS, Girardi FP, Cammisia FP Jr, Sama AA. *J Neurosurg Spine*. 2012 Apr;16(4):329-33. Epub 2012 Jan 27. PMID: 22284229
5. A radiographic assessment of the ability of the extreme lateral interbody fusion procedure to indirectly decompress the neural elements. Oliveira L, Marchi L, Coutinho E, Pimenta L. *Spine (Phila Pa 1976)*. 2010 Dec 15;35(26 Suppl):5331-7. PMID: 21160997
6. Continuous intraoperative electromyographic recording during spinal surgery. Beatty RM, McGuire P, Moroney JM, Holladay FP. *J Neurosurg*. 1995 March; Vol. 82:401-405.